

ORIGINAL ARTICLE

Torsional Anomalous Retinal Correspondence Effectively Expands the Visual Field in Hemianopia

PremNandhini Satgunam* and Eli Peli†

ABSTRACT

Purpose. Exotropia in congenital homonymous hemianopia has been reported to provide field expansion that is more useful when accompanied with harmonious anomalous retinal correspondence (HARC). Torsional strabismus with HARC provides a similar functional advantage. In a subject with hemianopia demonstrating a field expansion consistent with torsion, we documented torsional strabismus and torsional HARC.

Methods. Monocular visual fields under binocular fixation conditions were plotted using a custom dichoptic visual field perimeter. The dichoptic visual field was also modified to measure perceived visual directions under dissociated and associated conditions across the central 50° diameter field. The field expansion and retinal correspondence of a subject with torsional strabismus (along with exotropia and right hypertropia) with congenital homonymous hemianopia was compared with that of another exotropic subject with acquired homonymous hemianopia without torsion and to a control subject with minimal phoria. Torsional rotations of the eyes were calculated from fundus photographs and perimetry.

Results. Torsional anomalous retinal correspondence documented in the subject with congenital homonymous hemianopia provided a functional binocular field expansion up to 18°. Normal retinal correspondence was mapped for the full 50° visual field in the control subject and for the seeing field of the acquired homonymous hemianopia subject, limiting the functional field expansion benefit.

Conclusions. Torsional strabismus with anomalous retinal correspondence, when occurring with homonymous hemianopia provides useful field expansion in the lower and upper fields. Dichoptic perimetry permits documentation of ocular alignment (lateral, vertical, and torsional) and perceived visual direction under binocular and monocular viewing conditions. Evaluating patients with congenital or early strabismus for HARC is useful when considering surgical correction, particularly in the presence of congenital homonymous hemianopia.

(Optom Vis Sci 2012;89:E1353–E1363)

Key Words: cyclotropia, exotropia, low vision, field loss, abnormal retinal correspondence

Homonymous hemianopia can be acquired or congenital.^{1,2} Congenital homonymous hemianopia is frequently diagnosed only in early adulthood, with the patient and family having no prior knowledge of the visual field defect.^{3–5} In some cases of congenital or presumed congenital homonymous hemianopia, exotropia of the eye ipsilateral to the visual field loss has been reported.^{6–11} For example, in right hom-

onymous hemianopia with right exotropia, the right eye covers more of the right field of view (Fig. 1B) than in orthotropia (Fig. 1A). A left esotropia would provide a similar field expansion effect, but with some reduction of the left temporal visual field (Fig. 1C). Reports of esotropia in congenital homonymous hemianopia are relatively unknown. We found only one such probable occurrence in the literature.⁴

As a result of strabismus, patients may experience diplopia (two images of the same object with different visual directions) and visual confusion (two different objects seen in the same visual direction).¹² Usually only diplopia is reported spontaneously. The field expansion illustrated in Fig. 1 may be less beneficial if accompanied by diplopia, as central diplopia can be disturbing and ill tolerated. It is possible to correct the diplopia with prisms or sur-

*BS(Opt), MS, PhD

†MSc, OD, FFAO

Schepens Eye Research Institute, Massachusetts Eye and Ear, and Department of Ophthalmology, Harvard Medical School, Boston, Massachusetts (PNS, EP).

Supplemental digital contents are available for this article. Direct URL citations appear in the printed text and are provided in the HTML and PDF versions of this article on the journal's Web site (www.optvissci.com).

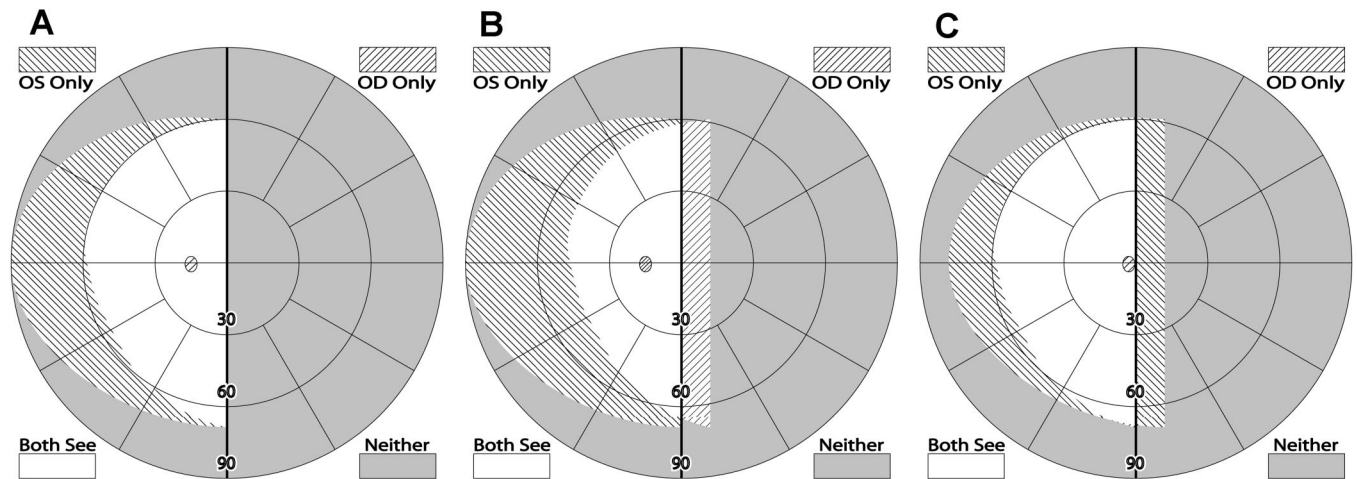


FIGURE 1.

Schematic binocular (dichoptic) visual field diagrams in right homonymous hemianopia illustrating the (A) binocular field in orthotropia (both eyes fixating). (B) Binocular field in right exotropia (left eye fixating). (C) Binocular field in left esotropia (right eye fixating). Field expansion is evident to the right of the vertical midline in the cases of lateral strabismus (B and C). However, with strabismus, the areas seen by both eyes (white) are diplopic, unless harmonious anomalous retinal correspondence (HARC) is developed.

gery,^{13,14} or avoid it by patching one eye. However, these treatments, if successful, also eliminate the field expansion benefit of the strabismus. For this reason, some strabismus surgeons consider congenital hemianopia a contraindication for strabismus surgery,⁶ in spite of the disagreement if the strabismus is a purposeful adaptation to congenital hemianopia or simply an epiphenomenon.^{10,15} Prisms are frequently fitted as an optical treatment for hemianopia.^{16,17} If a prism sector is fitted unilaterally (on one lens only) and when the patient's gaze is directed through the prism toward the field loss, central diplopia occurs,¹⁸ similar to acquired strabismus. The strabismus (exotropia, if the prism is fitted base-out) is optically induced by the prism.¹⁹ Again, if the diplopia is resolved either by fusing the images through the prisms or by suppression, the field expansion effect is eliminated.²⁰

Sensory adaptations such as suppression or anomalous retinal correspondence (ARC) may develop in the presence of strabismus occurring in the early years of development.^{21–23} Suppression may be total, affects the whole field, or may be partial, affects only the fovea of the deviating eye or peripheral locus in the deviating eye directed in the same direction as the fovea of the fixating eye.²⁴ If suppression is total, the exotropia may not provide an effective field expansion for patients with hemianopia, as the potentially expanded field is suppressed. If suppression is partial, there may be some field expansion peripherally but not centrally.²⁰ We are not aware of any reports of measured suppression either total or central, as an adaptation in hemianopia with strabismus or with prismatic correction for hemianopia.

ARC is a sensory adaptation wherein the correspondence of the two eyes gets remapped in such a way that a nonfoveal region in the deviating eye has the same visual direction as the fovea of the fixating eye, thus angle of remapping is equal to the angle of the deviation^{12,25} enabling the fixated object to be perceived single, despite the strabismus. This results in harmonious ARC (HARC). HARC eliminates both diplopia and confusion (but provides only poor stereopsis).²⁶ If the exotropia is accompanied by HARC in patients with hemianopia the panoramic visual field expansion is considered to be fully functional and provides veridical visual di-

rection across the whole field, including the expanded field. The adaptation may be a combination of suppression and HARC. If central suppression is to be combined with HARC only peripherally the adaptation may be of intermediate benefit, less effective than full field HARC but more functional than central suppression without HARC.

Torsion or cyclorotation is the rotation of the eye around its visual axis.^{27–31} Torsion without a known cause is called anatomic torsion.³² Torsional strabismus frequently goes unnoticed, especially when congenital. This is because of patients' lack of reporting symptoms of torsional diplopia presumed to be due to sensory-motor adaptations.²⁸ Detection of anatomic torsion depends mainly on objective measurement by indirect ophthalmoscopy, fundus photography, or perimetry (relative rotational shift between the physiological blind spot and the fovea).^{28,32,33} With fundus imaging and with conventional perimeters, torsion can only be measured monocularly. Thus, it may represent cyclophoria that should disappear under binocular viewing condition. Cyclophoria should result in perceived relative rotation of the two eyes' images under dissociated binocular condition (i.e., in the synoptophore or using the double Maddox rod test). In torsional strabismus or cyclotropia, the eyes will remain counter rotated under binocular viewing condition. This should result in constant torsional diplopia (as happens with acquired torsional strabismus) or single binocular vision under either full suppression or torsional HARC, a phenomenon demonstrated here.

Hemianopia in a patient with torsional strabismus provides an opportunity to record the cyclorotated visual fields (counter rotated vertical meridians) under both monocular and binocular perimetry along with the rotated blind spot of one eye in monocular perimetry (Fig. 2). Torsional strabismus in conjunction with hemianopia also provides field expansion. For a right hemianopia with intorsion, a superior field expansion results from the left eye's intorsion, whereas the right eye contributes a field expansion inferiorly (Fig. 2A). The field expansion effects due to both lateral and torsional deviation add up providing a wider overall field expan-

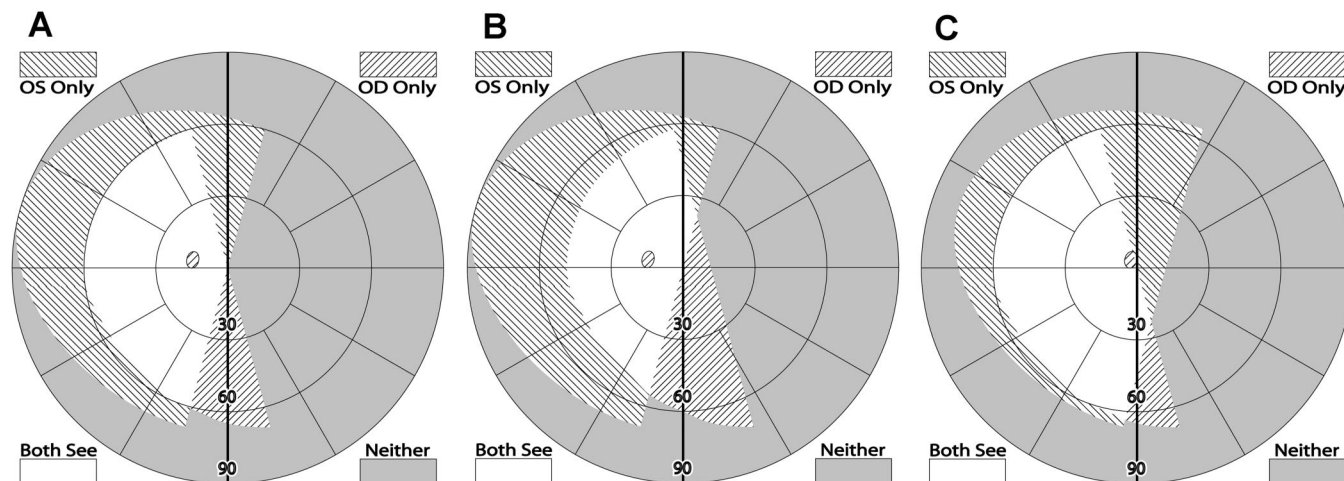


FIGURE 2.

Schematic binocular visual field diagrams illustrating the visual field expansion in right homonymous hemianopia with torsional strabismus. Field expansion is evident to the right of the vertical midline. Areas seen by both eyes (white) are diplopic unless HARC is developed. (A) Intorsion, the superior field expansion is from left eye and the inferior field expansion is from the right eye, (B) right exotropia with intorsion (left eye fixating), (C) left esotropia with intorsion (right eye fixating). The field expansion is illustrated by the areas seen by either eye to the right of the vertical midline.

sion (Fig. 2B, C). In the presence of HARC, such expansion would be most useful. Functional field expansion due to torsional deviation has not been reported before.

In the presence of strabismus, the monocular and binocular visual fields could differ considerably. If a visual field expansion is recorded under binocular conditions, it is difficult to ascertain whether the fixating or the deviating eye (in the absence of suppression) detected the target. With a dichoptic perimeter, the patient can be provided with a binocular fixation target (or even a complex background seen binocularly), whereas the monocular visual fields are measured with dichoptic stimuli.^{34,35} We used our dichoptic perimeter (mentioned in Methods) to investigate the retinal correspondence and visual fields of patients with homonymous hemianopia and strabismus.

METHODS

Subjects

A 44 year-old man (subject 1) had presumed congenital right homonymous hemianopia detected at age 12 years with the onset of seizures. The field loss in this subject was presumed to be due to a stroke in infancy. Subject also reported that he had a “weak” right eye and was prescribed patching of the left eye in early childhood. He drives occasionally and does not have any complaints about mobility. This subject was seen in our laboratory to participate in a study evaluating the effect of peripheral prisms.³⁶

A 56-year-old woman (subject 2) with acquired left homonymous hemianopia and a 46-year-old man (subject 3) with normal binocular vision, full visual fields, and no systemic health problem were recruited as control subjects. Vision measurements for the three subjects are summarized in Table 1.

Measuring Torsion from Retinal Images

The Nidek MP-1 Micro Perimeter (Nidek Technologies, Vigonza, Italy) was used to measure eye fixation and obtain retinal photos, whereas the subjects fixated on a white 2° cross. The retinal

photo was used to measure the positional relationship between the optic nerve head and the fovea. Torsional magnitude can be calculated by anchoring the optic disc and measuring the rotated foveal position.^{32,37} Since visual field testing is centered on the foveal fixation, we chose to calculate the rotation of the optic disc around the fovea. A custom program (Matlab R2007b, The MathWorks Inc., MA) developed in our laboratory³⁸ was used to estimate the optic disc center. The average distance from the optic disc to the fovea is 15.1° horizontally and 2° vertically above the fovea.³⁹ The angle between the observed optic disc center and the calculated optic disc center gives the measure of torsional movement (Fig. 3). When the eye is intorted, the optic disc is situated below the fovea (corresponding to superior location of the blind spot in the visual field).

Visual Fields

Monocular and binocular visual fields were measured kinetically with Goldmann perimeter (V4e) and dichoptic visual fields (DVF) system. The DVF is a custom perimeter³⁴ that allows presentation of different perimetric stimuli to each eye independently under binocular (or monocular) fixation conditions using a liquid crystal shutter goggles.

The ferroelectric liquid crystal shutter goggles permit about 60° diameter of visual field to be tested with the DVF. The subject fixated on a 1.2° central fixation cross seen binocularly and was instructed to press a button when a 1.2° square target seen only monocularly was detected.

Mapping Retinal Correspondence

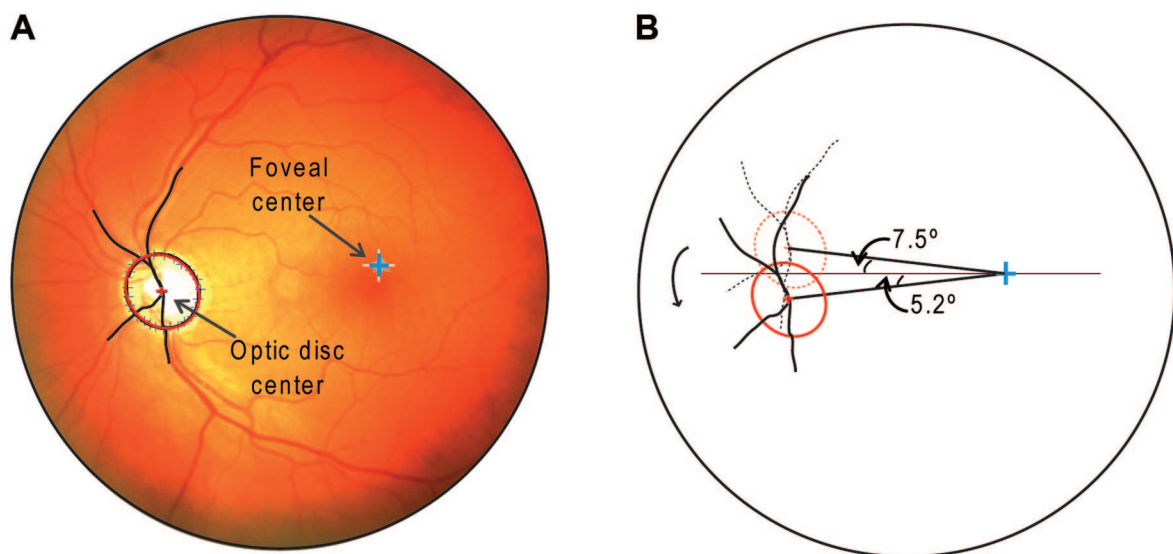
Perceived visual directions were mapped over the central 50° diameter of the visual field (pericentral field) by modifying the DVF. A fixation target (1.2° cross centered inside a 3° box) was presented on a gray background (Fig. 4). A 3° open square frame was presented in 1 of 16 preselected peripheral positions. The fixation target and the open frame were always viewed by the same

TABLE 1.

Vision testing results

Tests	Subject 1	Subject 2	Subject 3
Visual fields	Right homonymous hemianopia	Left homonymous hemianopia	No field defects
Hirschberg test	Left eye fixating and pupillary reflex in right eye is off-center to left 0.6 mm (calculated from photograph)	Intermittent alternating exotropia (right eye more often drifts into tropia position)	Orthotropia
Cover test	Dist: 6 Δ RXT Near: 12 Δ RXT 10 Δ Right hypertropia (for distance and near)	Dist: 8 Δ AXT Near: 18 Δ AXT	Dist: Orthophoria Near: 2 Δ exophoria
Worth four-dot test	Alternating between diplopia and suppression (OD)	Diplopia: 2 red, 3 green	Fusion: 1 red, 3 green
Bagolini lenses	Crossing of lines forming "X" at the light	Alternating suppression of the entire line	Crossing of lines forming "X" at the light
Double Maddox rod test	No torsion found	Not done	No torsion found
Torsion calculated from fundus image (physiological limits: $\leq 9^\circ$ per eye ³²)	OD: 13.5° intorsion OS: 12.7° intorsion	OD: 3.1° intorsion OS: 4.0° extorsion	OD: 2.5° intorsion OS: 4.3° intorsion
Stereopsis Randot circles (Precision Vision, La Salle, IL)	None: <500'	400'	20'
Sighting Dominance (hole in the card test)	Left eye	Right eye	Right eye
Visual acuity	Right eye: 20/25 Left eye: 20/20 Both eyes: 20/25	Right eye: 20/20 Left eye: 20/20 Both eyes: 20/20	Right eye: 20/32 Left eye: 20/32 Both eyes: 20/25
Extraocular motility	Full, free and painless	Full, free and painless	Full, free and painless

RXT, right exotropia; AXT, alternating exotropia.

**FIGURE 3.**

(A) Left eye fundus with optic disc margin and blood vessels traced. Foveal and optic disc centers are marked and used in calculations. (B) Estimated normal position of the optic disc (dashed ellipse) center relative to the fovea is calculated from the known anatomical relationship. Angle of intorsion (12.7°) is measured between observed (solid ellipse) and estimated positions of the optic disc. A color version of this figure is available online at www.optvissci.com.




FIGURE 4.

Subject maintained fixation on the projected central fixation cross inside a frame. Under subject's instruction, the filled square target was moved to align it to the center of the open frame under dichoptic viewing conditions. Retinal correspondence was thus measured using alignment of nonfusible peripheral targets.

eye(s). A 1.2° filled square target was moved with the computer mouse by the examiner as directed by the subject verbally until the subject perceived the square target to be aligned to the center of the open frame. The visibility of the square target was different in three conditions described later in the text. Subjects were instructed to fixate on the cross at all times. To ensure accurate fixation, eye movements of subject 1 were monitored with an infra-red camera (Supercircuit, PC6 \times 3, 16 mm). Eye movements were not monitored for the control subjects but their failure to detect targets shown in the blind spot and in the blind hemifield confirmed accurate fixation.

Three test conditions were used to map retinal correspondence:

1. Primary deviation: Fixation target and open frame were viewed by the dominant/nondeviating eye, and the square target was presented to the nondominant/deviating eye. The dominant eye for the subjects was selected using the sighting dominance test (Table 1).
2. Secondary deviation: Fixation target and open frame were viewed by the nondominant/deviating eye, and the square target was presented to the dominant/nondeviating eye.
3. Binocular viewing: Fixation target, open frame, and the square target were all viewed by both eyes. This simulated the natural viewing conditions.

RESULTS

All the subjects had stable foveal fixation measured with the Nidek MP-1. HARC was noted for Subject 1 with the Bagolini lens test (crossing of the lines ("X") at the center of the light, subject reported intermittent fading of the right eye line). Prism neutral-

ization of the right exotropia (cover test measured) resulted in reported uncrossed diplopia, supporting the diagnosis of ARC. Subject 1 also had intorsion (13.5° in the right eye and 12.7° in the left eye) measured from the retinal photos (shown for the left eye in Fig. 3). Intorsion for this subject was also evident from the visual field plots, by the superiorly rotated physiological blind spot of the left eye in both monocular fixation (Fig. 5) and binocular viewing (Fig. 6). Torsional rotation of the eyes for the two control subjects (Table 1) was well within the established physiological variability ($\leq 9^\circ$ per eye).³²

Visual Fields

The binocular Goldmann fields and the monocular plots under binocular viewing conditions measured with the DVF system are shown in Figs. 6 to 8. For subject 1 (Fig. 6), Goldmann binocular visual field with the dominant left eye fixating shows what appears to be an incomplete right hemianopia with about 5° residual in the central visual field and up to 25° residual in the inferior field. The corresponding monocular DVF plot under the same binocular fixation shows a 5° lateral expansion from the right eye and that the superior and inferior field to the right of the midline is actually expansion resulting from the intorsion of the left eye and right eye, respectively. Intorsion also causes the blind spot to rotate superiorly (10.5°), as can be seen in the left eye visual field plot (see online supplementary material for more visual field discussion). The blind spot for the control subjects (Figs. 7 and 8) were found at the expected physiological position (the temporally shifted blindspot in the right eye for subject 2 (Fig. 7) corresponds with the exotropia).

Retinal Correspondence

All the three subjects were able to perform the visual directions mapping task (Fig. 9). Subject 1 closely aligned the square target to the center of the open frame in the seeing field in all the three test conditions. This demonstrates HARC that compensated for horizontal, vertical, and torsional deviations across the tested field. The right eye repeatedly saw one target in the right inferior field (along the 290° meridian at eccentricity of about 25°) consistent with the Goldmann and DVF visual field plot of the right eye. A target presented close to the blind spot in the left eye was seen by the left eye and aligned by the subject. The subject reported this target to fade at times, but he was able to see it most of the time. This could have resulted from small fixational eye movements.

Both the control subjects showed normal retinal correspondence. The exotropic state of the eye was manifested in Subject 2 under dissociated conditions (monocular viewing) across the whole field. Note that this results in a field expansion but with erroneously perceived visual directions. This subject reported the fixation cross to appear double intermittently in the binocular viewing conditions. Retinal correspondence was mapped only when the fixation cross appeared single in the binocular viewing condition. The subject found it tiring to do the binocular viewing condition, as it forced fusion to be maintained. The subject was unable to perform the task for certain targets in the pericentral region under the binocular fixation condition. When maintaining fusion, the targets were more closely aligned. Subject 3 had the targets all closely aligned in all the three conditions.

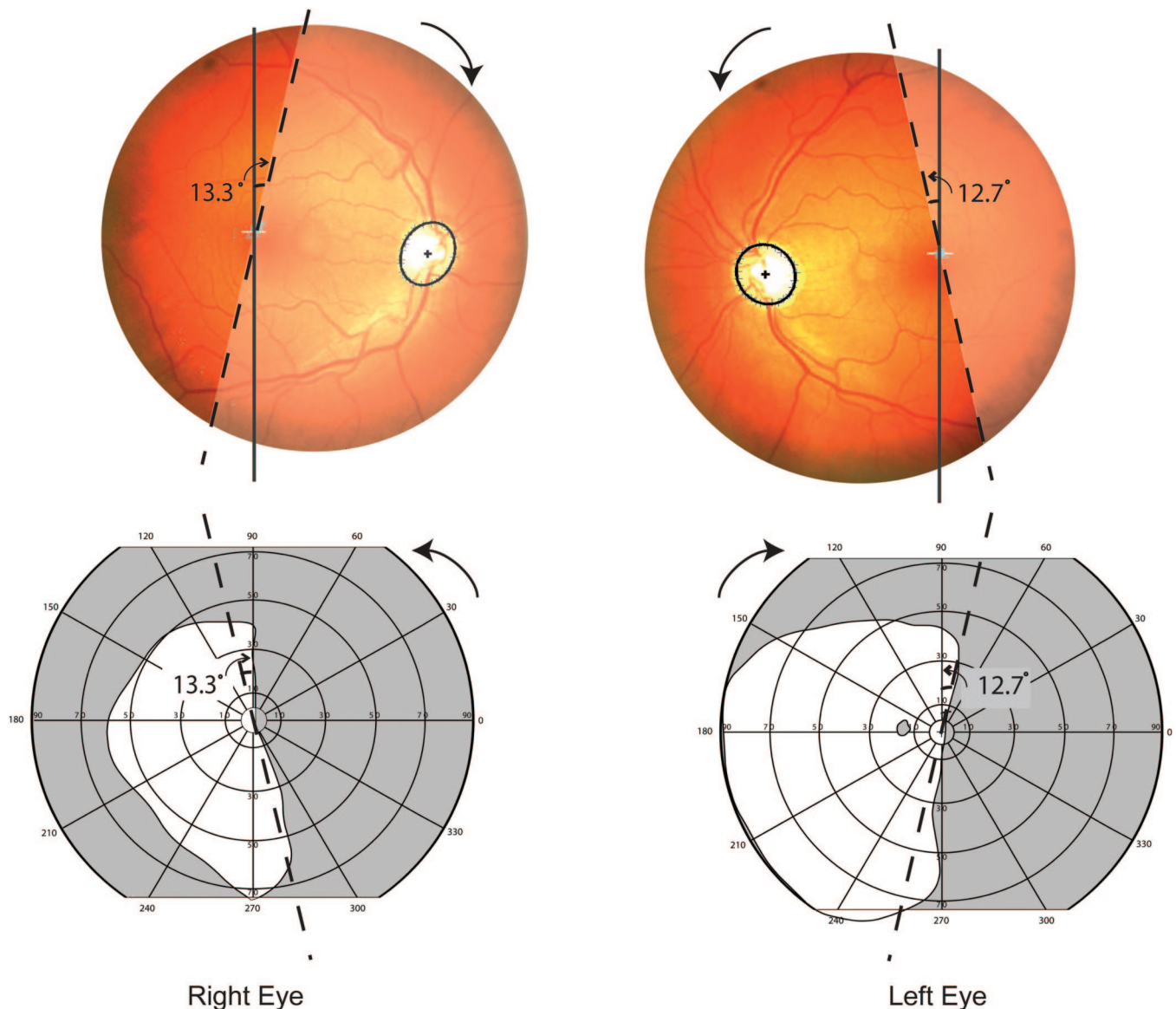


FIGURE 5.

Fundus photos for each eye and the corresponding monocular Goldmann visual fields are shown. Retinal areas corresponding to the hemianopic field are shown in lower contrast. Superior position of the left eye's physiological blind spot in the left eye field indicates intorsion. The dashed lines in corresponding retina and field diagrams are rotated by the amount measured from the retinal images. A color version of this figure is available online at www.optvissci.com.

DISCUSSION

The prior cases of reported exotropia in homonymous hemianopia^{6-9,11} had larger magnitudes of exotropia ($\geq 20\Delta$ or about 10°) than subject 1 (10Δ), who only had about 5° lateral expansion of his visual field. However, the presence of modest torsional strabismus increased the binocular visual field to a much greater extent. Due to incyclotropia, this subject had a greater inferior (about 18°) and superior (about 15°) visual field expansion, as expected (Fig. 2B). This field expansion was repeatable (Appendix, available at <http://links.lww.com/OPX/A99>), and with stable fixation documented for this subject, it cannot be attributed to measurement noise from eye movements.⁴⁰ The magnitude of the field expansion is substantial in considering that legal blindness due to field loss is declared only when the residual field is below 20° in diameter (10° on each side of the vertical meridian).⁴¹ The presence of

inferior visual field expansion is particularly useful for mobility.⁴² In addition, presence of HARC eliminated torsional (as well as lateral and vertical) diplopia and visual confusion in the residual visual field. Torsional strabismus should be suspected when there is a combination of both horizontal and vertical strabismus.^{28,37}

ARC is commonly found in esotropia.^{43,44} However, exotropia that develops at a younger age in patients with hemianopia is frequently associated with ARC^{6,7,9} (The Iwashige et al.⁸ study was published in Japanese, and we are unable to confirm that their patients had exotropia at a younger age. Since their subjects had ARC, it can be assumed they did). Congenital or early childhood hemianopia with absence of strabismus is also reported in the literature.⁴⁵ Although it is unclear whether strabismus is actually developed as a compensatory mechanism for the field loss,^{10,15} it is clear that strabismus in conjunction with HARC is advantageous

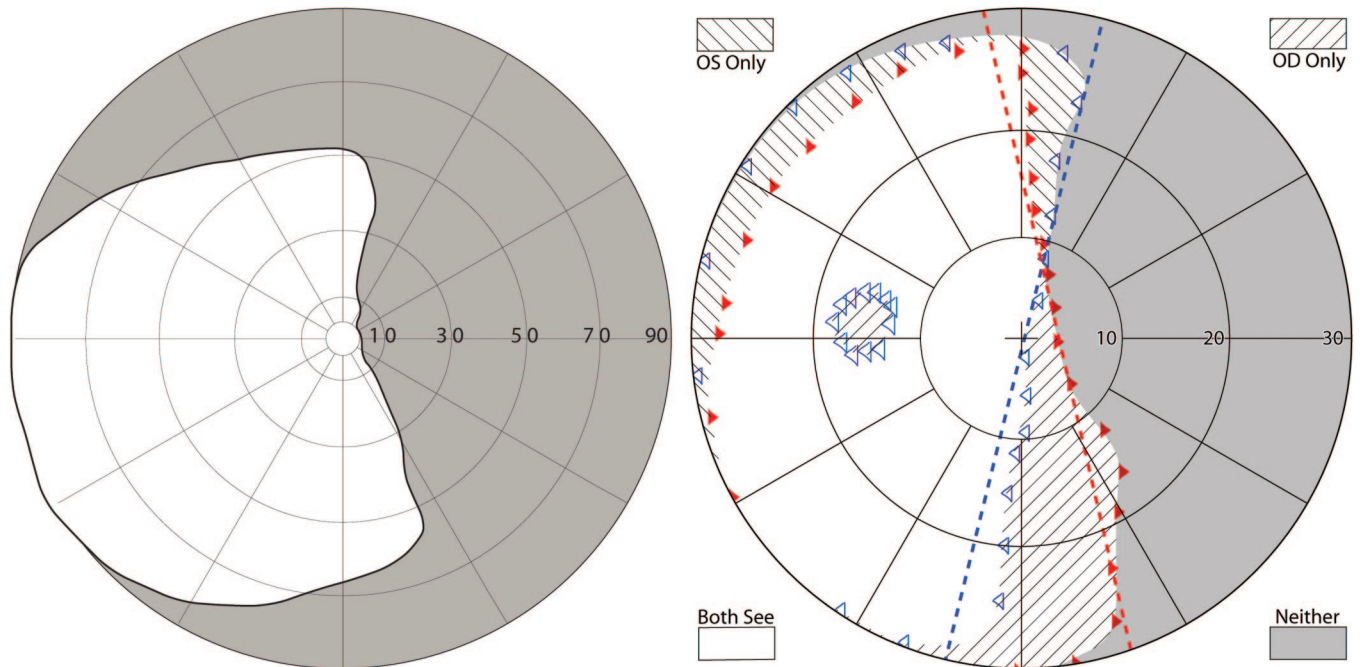


FIGURE 6.

Binocular Goldmann visual field plots (left) and dichoptic visual field (DVF) plots (right) are shown for subject 1. DVF fields are restricted by the goggles to only 60°. DVF plots were mapped under binocular viewing condition (central binocular fixation) while presenting monocular targets. Monocular targets detected by the right eye are shown as filled red triangles pointing to right and those detected by the left eye are shown as open blue triangles pointing to left. Rotation of the vertical meridian due to measured intorsion (from Nidek images) are marked by the dashed lines (red and blue) for right and left eye, respectively. The apparent restricted nasal fields are artifacts due to the mismatch between the subjects' and the goggles' pupillary distances. A color version of this figure is available online at www.optvissci.com.

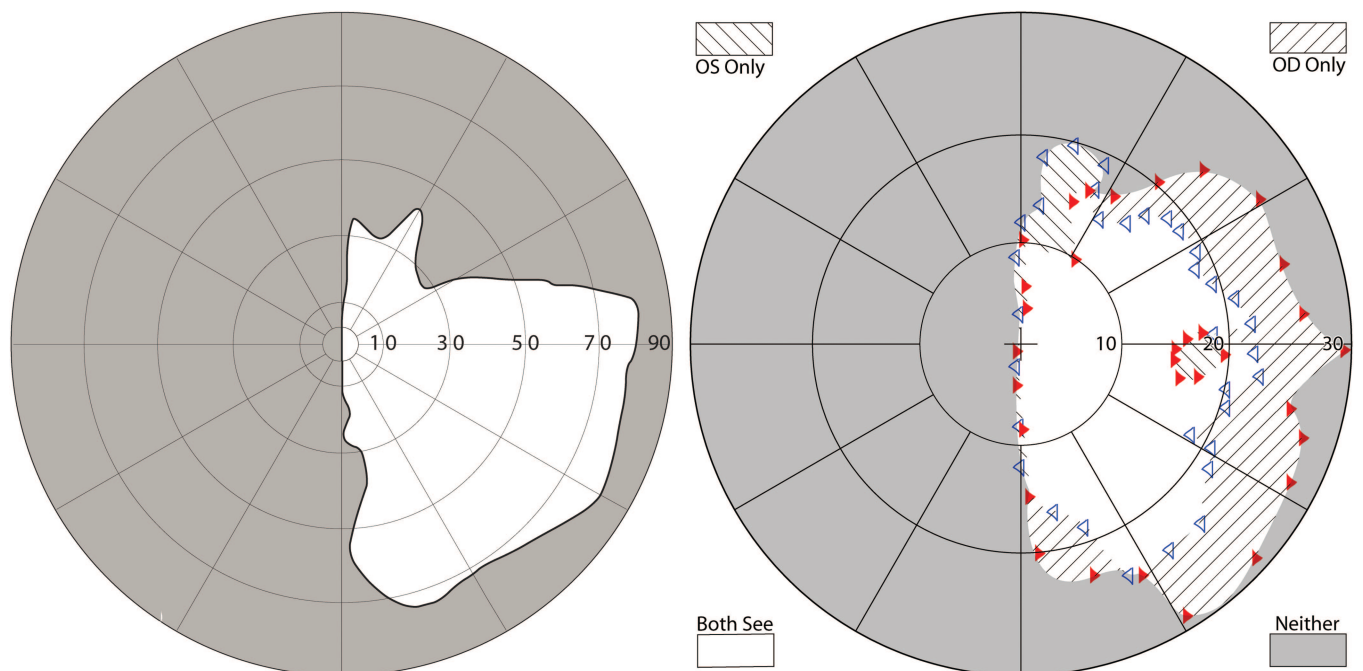


FIGURE 7.

Binocular Goldmann visual field plots (left) and dichoptic visual field (DVF) plots (right) are shown for subject 2. Figure follows the same conventions as Fig. 6. A color version of this figure is available online at www.optvissci.com.

for congenital or early childhood hemianopia. Unfortunately, it has not been proved possible to induce lateral strabismus with HARC in adult onset of hemianopia. Peli¹⁹ proposed a peripheral prism device that effectively induced “peripheral exotropia” as a

treatment for such patients. The technique has been found to be successful and provides expanded field shown to aid in obstacle detection.^{36,46,47} However, an HARC-like adaptation to the peripheral prism postulated by Peli¹⁹ has not been seen.²⁰

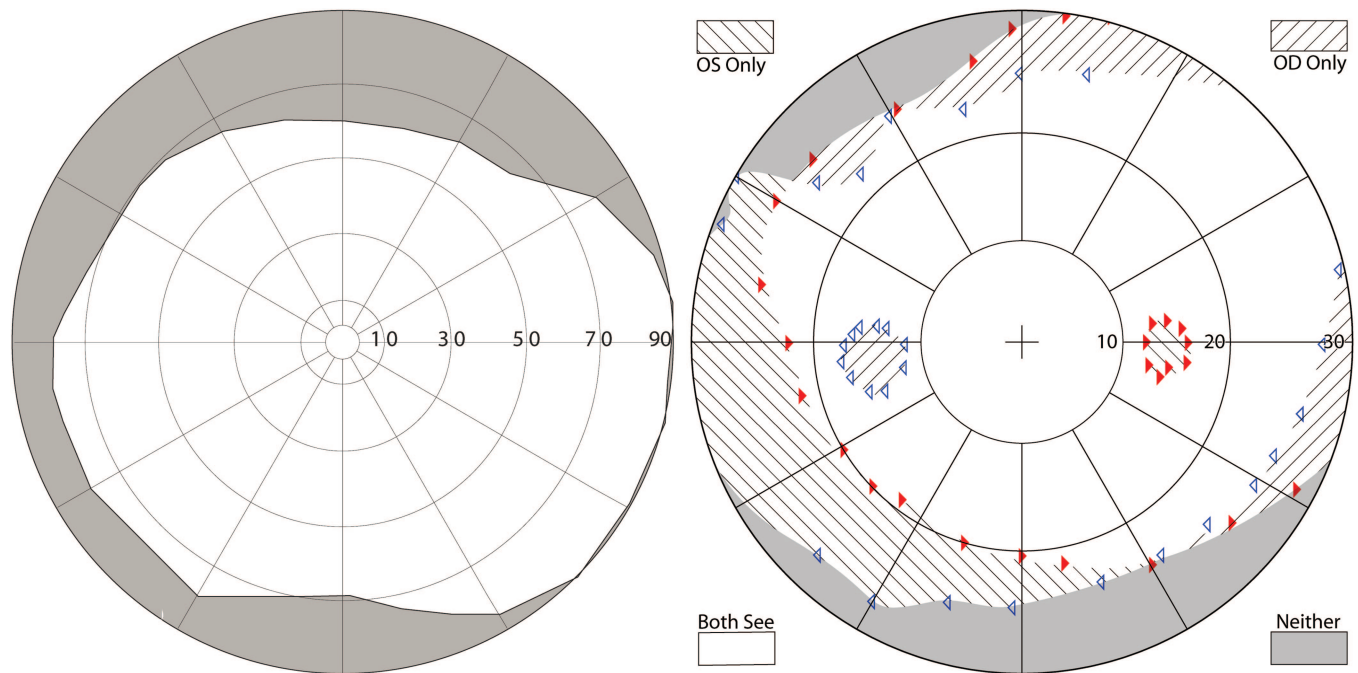


FIGURE 8.

Binocular Goldmann visual field plots (left) and dichoptic visual field (DVF) plots (right) are shown for subject 3. Figure follows the same conventions as Fig. 6. A color version of this figure is available online at www.optvissci.com.

Torsional HARC is interpreted clinically from mere absence of torsional diplopia in the presence of monocularly measured torsion.²⁸ Lack of complaints of torsional diplopia could be because of torsional motor fusion or from the masking by large horizontal or vertical deviations that might interfere with the patient's ability to perceive torsional diplopia.²⁷ However, it is also possible that HARC could develop with torsional strabismus because distances between corresponding directions on both retinas increases gradually with retinal eccentricity in conjunction with the increase in Panum's fusional areas.⁴⁸ This suggests that if torsional strabismus can be induced in adult onset hemianopes either surgically or optically, it could provide much better field expansion, particularly the lower field needed for safe mobility as well as the overhead field protecting from obstacles such as tree branches. With better directional adaptation possibly with HARC-like adaptation, such a field expansion would be beneficial. Optical rotation is currently possible with either Dove prisms, which in addition to rotation also invert the image and are too large and heavy to be used in spectacle lenses, or with twisted fiber optic bundle used in night vision devices, which is also not suitable for this application. It may be possible to create an image-rotating lens using some novel optical techniques (and a lens of that sort may provide an improved approach to optical correction for hemianopia). Such lens may be restricted to the periphery, as in the Peli peripheral prisms,¹⁹ maintaining central single binocular vision but increasing field expansion with eccentricity. The image rotation may be introduced gradually, thus facilitating more tolerable cyclofusion in the larger peripheral Panum's area, as the development of ARC in adults are not documented. Testing of this concept may be initiated using a binocular head-mounted display in which the image in one eye is rotated computationally. Such a device would make it possible to determine the viability of the concept, and if successful, motivate efforts to develop the required optical elements.

ARC is more easily observed in testing conditions that closely resemble real-world targets or natural viewing tests such as Bagolini striated glasses, when compared with other dissociating tests such as the Worth four-dot test.^{44,49} The DVF system used in this study can provide a natural viewing state as well as dissociated conditions in the same instrument and with the same targets. In the present study, we did not use real-world images with the DVF resulting in a dissociated (or weakly associated) conditions. The presence of ARC under this condition is a stronger indication of HARC as seen in subject 1.

Retinal correspondence has been reported to vary between the central and peripheral visual fields on some strabismic patients⁵⁰ without any visual field defects. One study noted the correspondence to be normal centrally and more anomalous in the peripheral visual field,⁵¹ whereas another study reported the opposite findings.⁵² With the DVF system we found that subject 1 maintained HARC both centrally and pericentrally (within the tested 50° visual field diameter) and under both primary and secondary deviations. Invariant level of HARC would be more useful as an adaptation for hemianopia. We believe that our method of direct measure of visual directions at different eccentricities provides a better estimate for retinal correspondence.

Lateral and vertical strabismus is manifested only in binocular viewing. Under monocular viewing, each eye takes up foveal fixation even with ARC (except in some parietic strabismus and eccentric fixation conditions). The difference in the strabismic eye position between monocular and binocular viewing (i.e., cover-uncover test) establishes the diagnosis (i.e., phoria/tropia). In purely torsional deviation (phoria/tropia), the eye's torsional movement is much harder to detect with direct observation under cover-uncover test. Most objective tests such as fundus photography indirect ophthalmoscopy and blind spot perimetry for measuring torsion are essentially monocular. The double Maddox rod




FIGURE 9.

Measurement of retinal correspondence with the DVF for each subject (subject 1-top row, subject 2-middle row, and subject 3-bottom row). Primary deviation (left panel): sighting dominant eye fixates (left eye for subject 1 and right eye for subjects 2 and 3) and the nondominant eye sees filled square targets to be aligned with the center of the open frame seen by the fixating eye. Secondary deviation (middle panel): nondominant eye now fixates (right eye for subject 1 and left eye for subjects 2 and 3), and the dominant eye sees the square targets to be aligned with the center of the open frame now seen by the nondominant eye. Binocular fixation (right panel): fixation target, square target, and the open frame (marked in the figure) were seen binocularly. Three-sided frames are used in the figure to aid in eye identification. A color version of this figure is available online at www.optvissci.com.

subjective test though viewed with both eyes dissociates binocular vision (in particular torsional fusion) and does not differentiate between a phoria and a tropia, similar to regular Maddox rod test for lateral and vertical deviation. Torsional rotation only under dissociated condition is indicative of cyclophoria and lack of diplopia under associated condition could result from torsional fusion (cyclofusion). The presence of homonymous hemianopia as in our subject 1 enables documentation with the DVF of the rotation of

the vertical meridian (as well as the physiological scotoma's rotation) under associated binocular fixation, thus establishing the torsion to be tropic. Such observation is not possible in standard perimetry without hemianopia. Further, the standard perimetry is only weakly binocularly associated in regard to torsion as the central fixation target while providing a sound fusional stimulus for lateral/vertical phoria provides minimal stimulus for torsional phoria. Additional peripheral targets are necessary to facilitate torsional

fusion. With dichoptic perimetry system, rotation of the physiological blind spot can be measured (without hemianopia) and compared under both monocular (not shown) and binocular fixation conditions (Fig. 6). The DVF can also present visually rich background for the perimetry that can serve as stimulus for torsional fusion. This enables differentiation of the torsional posture under associated and dissociated binocular conditions (with a tropic eye remaining in the torsional position under both conditions). Thus, a dichoptic perimeter with the capabilities of the DVF provides a unique testing environment for a more complete evaluation of torsion and of torsional HARC. In our patient, despite the less optimal blank background, HARC was demonstrated indicating a stronger adaptation.

To our knowledge, this is the first reported torsional HARC in a patient with homonymous hemianopia.

ACKNOWLEDGMENTS

Supported in part by NIH grants EY07957 and EY12890 and P30EY003790. Henry Apfelbaum helped prepare the illustrations.

Received December 5, 2011; accepted June 4, 2012.

APPENDIX

The appendix is available online at <http://links.lww.com/OPX/A99>.

REFERENCES

- Huber A. Homonymous hemianopia. *Neuroophthalmology* 1992; 12:351–66.
- Zhang X, Kedar S, Lynn MJ, Newman NJ, Bioussé V. Homonymous hemianopias: clinical-anatomic correlations in 904 cases. *Neurology* 2006;66:906–10.
- Bosley TM, Kiyosawa M, Moster M, Harbour R, Zimmerman R, Savino PJ, Sergott RC, Alavi A, Reivich M. Neuro-imaging and positron emission tomography of congenital homonymous hemianopias. *Am J Ophthalmol* 1991;111:413–8.
- Shinder R, Wolansky L, Turbin RE. Congenital homonymous hemianopia and cortical migration abnormalities in a young adult. *J Pediatr Ophthalmol Strabismus* 2009;46:38–41.
- Kedar S, Zhang X, Lynn MJ, Newman NJ, Bioussé V. Pediatric homonymous hemianopia. *J AAPOS* 2006;10:249–52.
- Herzau V, Bleher I, Joos-Kratsch E. Infantile exotropia with homonymous hemianopia: a rare contraindication for strabismus surgery. *Graefes Arch Clin Exp Ophthalmol* 1988;226:148–9.
- Göte H, Gregersen E, Rindziunski E. Exotropia and panoramic vision compensating for an occult congenital homonymous hemianopia: a case report. *Binocul Vis Eye Muscle Surg Q* 1993;8: 129–32.
- Iwashige H, Hirose O, Usui C, Shoda S, Miyasaka H, Maruo T. Surgical and botulinum toxin treatment in two cases of abnormal retinal correspondence-exotropia with congenital homonymous hemianopsia [in Japanese]. *Nihon Ganka Gakkai Zasshi* 1995;99: 1036–44.
- Levy Y, Turetz J, Krakowski D, Hartmann B, Nemet P. Development of compensating exotropia with anomalous retinal correspondence after early infancy in congenital homonymous hemianopia. *J Pediatr Ophthalmol Strabismus* 1995;32:236–8.
- Donahue SP, Haun AK. Exotropia and face turn in children with homonymous hemianopia. *J Neuroophthalmol* 2007;27:304–7.
- Gamio S, Melek N. When the patient says no. Management of exotropia with hemianopic visual field defects. *Binocul Vis Strabismus Q* 2003;18:167–70.
- Duke-Elder S, Wybar K. *System of Ophthalmology*. London, UK: H. Kimpton; 1973.
- Phillips PH. Treatment of diplopia. *Semin Neurol* 2007;27:288–98.
- Rucker JC, Tomsak RL. Binocular diplopia. A practical approach. *Neurologist* 2005;11:98–110.
- Hoyt CS, Good WV. Ocular motor adaptations to congenital hemianopia. *Binocul Vis Eye Muscle Surgery Q* 1993;8:125–6.
- Smith JL, Weiner IG, Lucero AJ. Hemianopic Fresnel prisms. *J Clin Neuroophthalmol* 1982;2:19–22.
- Cohen JM, Weiss B. Visual field remediation. In: Cole RG, Rosenthal BP, eds. *Remediation and Management of Low Vision*. St. Louis, MO: Mosby; 1996:1–25.
- Gottlieb DD. *Living with Vision Loss*. Atlanta, GA: St. Barthelémy Press, Ltd.; 1996.
- Peli E. Field expansion for homonymous hemianopia by optically induced peripheral exotropia. *Optom Vis Sci* 2000;77:453–64.
- Giorgi RG, Woods RL, Peli E. Clinical and laboratory evaluation of peripheral prism glasses for hemianopia. *Optom Vis Sci* 2009;86: 492–502.
- Pickwell D. *Binocular Vision Anomalies: Investigation and Treatment*, 2nd ed. London, UK: Butterworths; 1989.
- Daw NW. *Visual Development*. New York, NY: Plenum Press; 1995.
- Verma A. Anomalous adaptive conditions associated with strabismus. *Ann Ophthalmol (Skokie)* 2007;39:95–106.
- Rutstein RP, Daum KM. *Anomalies of Binocular Vision: Diagnosis and Management*. St. Louis, MO: Mosby; 1998.
- Kirschen DG. Understanding sensory evaluation. In: Rosenbaum AL, Santiago AP, eds. *Clinical Strabismus Management: Principles and Surgical Techniques*. Philadelphia, PA: Saunders; 1999:22–36.
- Harley RD, Nelson LB, Olitsky SE. *Harley's Pediatric Ophthalmology*, 5th ed. Philadelphia, PA: Lippincott Williams & Wilkins; 2005.
- Woo SJ, Seo JM, Hwang JM. Clinical characteristics of cyclodeviation. *Eye (Lond)* 2005;19:873–8.
- Philips PH, Hunter DG. Evaluation of ocular torsion and principles of management. In: Rosenbaum AL, Santiago AP, eds. *Clinical Strabismus Management: Principles and Surgical Techniques*. Philadelphia, PA: Saunders; 1999:52–72.
- Guyton DL. Strabismus complications from local anesthetics. *Semin Ophthalmol* 2008;23:298–301.
- Holgado S, Enyedi LB, Toth CA, Freedman SF. Extraocular muscle surgery for extorsion after macular translocation surgery new surgical technique and clinical management. *Ophthalmology* 2006;113: 63–9.
- Dieterich M, Brandt T. Ocular torsion and perceived vertical in oculomotor, trochlear, and abducens nerve palsies. *Brain* 1993;116(Pt. 5):1095–104.
- Guyton DL. Clinical assessment of ocular torsion. *Am Orthopt J* 1983;33:7–15.
- Morton GV, Lucchese N, Kushner BJ. The role of funduscopy and fundus photography in strabismus diagnosis. *Ophthalmology* 1983; 90:1186–91.
- Woods RL, Apfelbaum HL, Peli E. DLP-based dichoptic vision test system. *J Biomed Opt* 2010;15:016011.
- Doherty AL, Bowers AR, Luo G, Peli E. Object detection in the ring scotoma of a monocular bioptic telescope. *Arch Ophthalmol* 2011; 129:611–7.
- Bowers AR, Keeney K, Peli E. Community-based trial of a peripheral prism visual field expansion device for hemianopia. *Arch Ophthalmol* 2008;126:657–64.

37. Kushner BJ, Hariharan L. Observations about objective and subjective ocular torsion. *Ophthalmology* 2009;116:2001–10.
38. Nugent AK, Keswani RN, Woods RL, Peli E. Contour integration in peripheral vision reduces gradually with eccentricity. *Vision Res* 2003;43:2427–37.
39. Hu SY, Schuchard RA, Fletcher DC, Sabates FN. Physiological blind spot characteristics and position relative to retinal locus for fixation by SLO testing. *Invest Ophthalmol Vis Sci* 1994;35:S1527.
40. Jamara RJ, Van De Velde F, Peli E. Scanning eye movements in homonymous hemianopia documented by scanning laser ophthalmoscope retinal perimetry. *Optom Vis Sci* 2003;80:495–504.
41. Colenbrander A. Visual standards, aspects and ranges of vision loss with emphasis on population surveys. Report prepared for the International Council of Ophthalmology at the 29th International Congress of Ophthalmology. Sydney, Australia: International Council of Ophthalmology; 2002:1–33.
42. Lovie-Kitchin J, Mainstone J, Robinson J, Brown B. What areas of the visual field are important for mobility in low vision patients? *Clin Vis Sci* 1990;5:249–63.
43. Katsumi O, Tanaka Y, Uemura Y. Anomalous retinal correspondence in esotropia. *Jpn J Ophthalmol* 1982;26:166–74.
44. Rutstein RP, Daum KM, Eskridge JB. Clinical characteristics of anomalous correspondence. *Optom Vis Sci* 1989;66:420–5.
45. Zangemeister WH, Meienberg O, Stark L, Hoyt WF. Eye-head coordination in homonymous hemianopia. *J Neurol* 1982;226:243–54.
46. Bowers AR, Keeney K, Apfelbaum DH, Peli E. Randomized controlled trial of oblique and horizontal peripheral prism glasses for hemianopia. *Optom Vis Sci* 2010;87:E-abstract 100960.
47. O’Neill EC, Connell PP, O’Connor JC, Brady J, Reid I, Logan P. Prism therapy and visual rehabilitation in homonymous visual field loss. *Optom Vis Sci* 2011;88:263–8.
48. Guyton DL. Ocular torsion: sensorimotor principles. *Graefes Arch Clin Exp Ophthalmol* 1988;226:241–5.
49. Nelson JI. A neurophysiological model for anomalous correspondence based on mechanisms of sensory fusion. *Doc Ophthalmol* 1981;51:3–100.
50. Sireteanu R, Fronius M. Different patterns of retinal correspondence in the central and peripheral visual field of strabismics. *Invest Ophthalmol Vis Sci* 1989;30:2023–33.
51. Haase W, Lung KH. Correspondence of foveal and peripheral areas in subjects with intact binocular vision and patients with strabismus [in German]. *Klin Monbl Augenheilkd* 1984;184:32–6.
52. Hallden U. The longitudinal horopter in a case of concomitant strabismus with anomalous correspondence. *Acta Ophthalmol (Copenh)* 1973;51:1–11.

Eli Peli

Schepens Eye Research Institute

20 Staniford Street

Boston, MA 02114-2500

e-mail: eli.peli@schepens.harvard.edu

APPENDIX - BUNDLE CROSS OVER

Typically with intorsion in a patient with HH, the visual fields of both eyes should show a rotation of the vertical meridian, as depicted in Figure 2. For Subject 1 however, only rotations of the lower half of the vertical meridian in the right eye and of the upper half of the vertical meridian in the left eye were noted (Figure 5). These effects were repeatable as seen from measurements made on two separate days (Figure A1). They suggest possible spared fiber or an anatomic variation¹ of bundle crossover in the chiasm resulting in sparing of an upper segment in the right eye and a lower segment in the left eye.

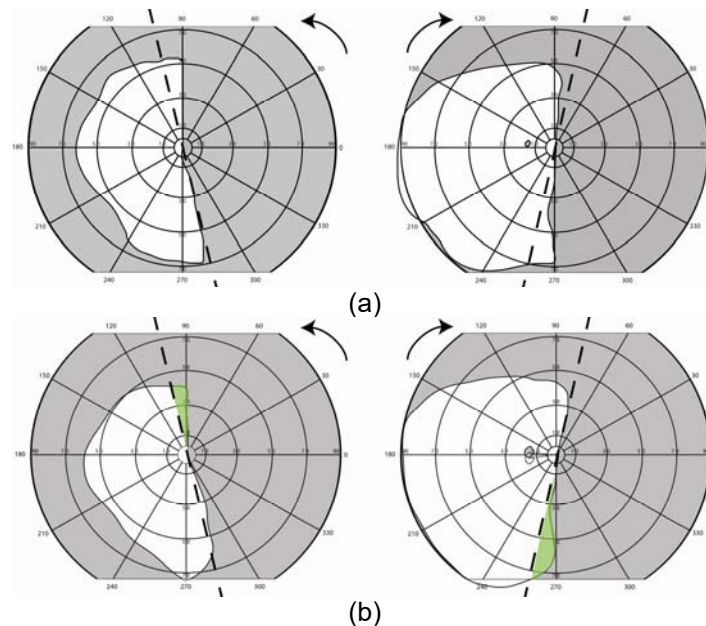


Figure A1: Monocular Goldmann visual fields were measured on two separate days show excellent repeatability (as in Fig. 5, left eye field is plotted on the right). Superior position of the left eye physiological blind spot in the left eye field indicates intorsion (target V4e for (a) and III4e for (b)). The expected rotation of the vertical meridian based on retinal photo torsion is marked by the tilted dashed lines. Additional residual visual fields in left (inferiorly) and right eye (superiorly) are highlighted in green (b). These could be due to spared/misdirected nerve fibers from the blinded hemi retina that ended in the spared hemisphere. Such crossing over is not rare but is rarely possible to notice except in cases of hemianopia.

¹ Younger BR. Midline tilting between seeing and nonseeing areas in hemianopia. Mayo Clinic proceedings 1976;51:562-8.